

3D CT Analysis of Combined Cup and Stem Anteversion in Cases of Cup Navigation in Hip Arthroplasty

GEORGI I. WASSILEW, MD; CARSTEN PERKA, MD; CHRISTIAN KOENIG, MSc; VIKTOR JANZ, MD; PATRICK ASBACH, MD; OLAF HASART, MD

abstract

Navigation of the cup in total hip arthroplasty is well analyzed and shows accurate results, reducing cup outliers of Lewinnek's "safe zone." With regard to the combined anteversion of cup and stem, however, a "new" safe zone with a range of 25° to 50° has been published. The aim of this study was to analyze total anteversion (cup and stem) by postoperative 3D computed tomography in isolated cup navigation cases. In 46 patients, the mean combined anteversion was 34.4° (range, 16.3°-57.3°, SD±9.3°) with 10 outliers. The mean cup anteversion was 19.5° (range, 11°-27°, SD±3.7°). Regarding Lewinnek's "safe zone" (cup only), we observed 5 outliers. An improvement of technique of stem implantation or navigation may reduce outliers of combined anteversion.

The correct positioning of the acetabular and femoral components during implantation of a total hip arthroplasty (THA) minimizes the risk of impingement and thus any potential complications such as accelerated polyethylene wear, osteolysis, and premature loosening of the implant.¹⁻⁴ Previous studies¹⁻⁶ examined the optimum position of the cup, where positioning in the "safe zone" according to Lewinnek et al,⁷ with an abduction of 40° (±10°) and an anteversion of 15° (±10°), was desired. If positioning of the acetabular cup occurs within this zone, then the risk of dislocation could be reduced.⁷

However, less has been published regarding positioning of the femoral component. A femoral anteversion of about 15° is desired.³⁻⁹ Although the anteversion may be readily controlled by the surgeon in the case of cemented endoprostheses, the resulting position when implanting a cementless press-fit stem may

be influenced by the geometry of the femoral neck, the antecurvature, and the cortical thickness of the femoral stem.^{10,11} However, depending on individual anatomic geometry, a larger anteversion of the stem is frequently accepted intraoperatively. Recent investigations show the importance of the correct positioning of acetabular and femoral components to prevent impingement of the femoral neck against the acetabular cup in different body positions.¹²

Hence, a combined anteversion (sum of the anteversion of the cup plus anteversion of the stem) for both components of 37° (range, 25° to 50°) was described to avoid impingement and a possible dislocation.^{8,9,12-14}

It is, therefore, possible that in previous studies in which only a navigation of the cup was performed, that the sought anteversion of the cup was achieved, but that the anteversion of the stem was not sufficiently taken into consideration.^{5,6,15,16}

The sum of the combined anteversions was not routinely achieved and, therefore, a higher proportion of outliers may be observed according to the concept of combined anteversion.¹⁴

Therefore, the aim of this study was to perform a retrospective analysis of the combined anteversion of both stem and cup by 3D computed tomography (CT) in THAs, wherein the cup was implanted with the aid of a navigation system but stem implantation occurred freehand.

In addition, it was to be determined whether a difference exists between the outliers using the concept of combined anteversion or the anteversion according to the Lewinnek's "safe zone."^{7,11}

MATERIALS AND METHODS

We included 46 patients in this retrospective study. Institutional Review Board

Drs Wassilew, Perka, Janz, and Hasart are from Charité Orthopaedic Department, Center for Musculoskeletal Surgery, Mr Koenig is from the Julius Wolff Institut, Charité Universitätsmedizin, and Dr Asbach is from Charité Department of Radiology, Charité Universitätsmedizin, Berlin, Germany.

Drs Wassilew, Janz, and Asbach and Mr. Koenig have no relevant financial relationships to disclose. Drs Hasart and Perka are consultants for Aesculap AG.

Correspondence should be addressed to: Georgi I. Wassilew, MD, Orthopedic Department, Charité, Charitéplatz 1, 10117, Berlin, Germany.

doi: 10.3928/01477447-20100510-53

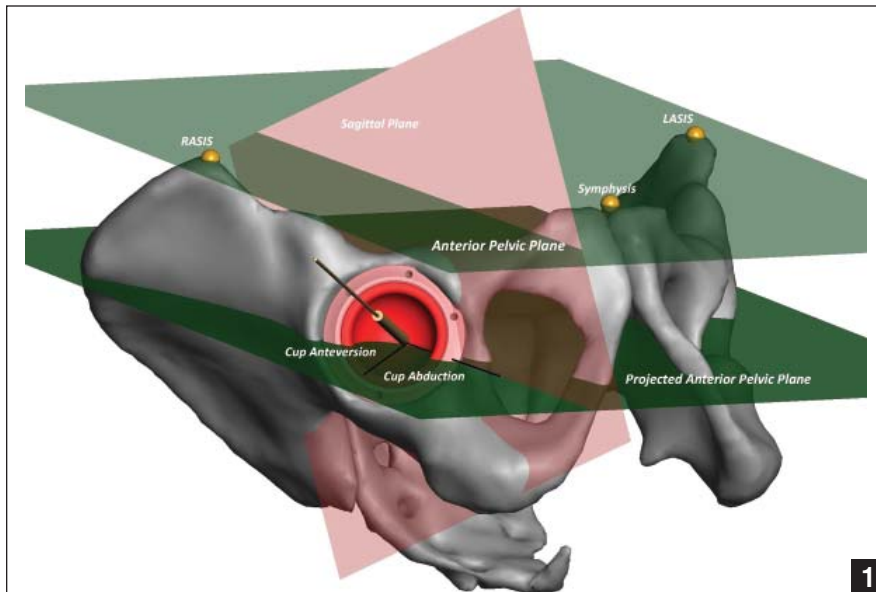


Figure 1: Orientation of the cup anteversion and abduction compared with anterior pelvic plane (LASIS, left anterosuperior iliac spine; RASIS, right anterosuperior iliac spine).

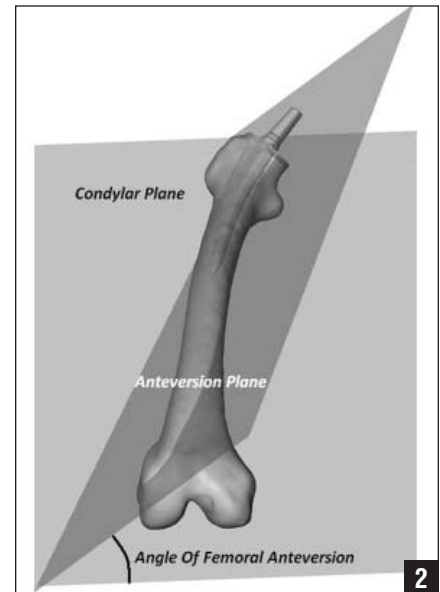


Figure 2: Femoral stem anteversion relative to the condylar plane (extreme stem anteversion of 39°).

approval for CT scans was obtained, as was informed consent for retrospective review of data from each patient. All patients underwent THA due to primary coxarthrosis. All operations were performed by a single surgeon using the same technique and a single cementless implant (Plasmacup and Excia stem; B. Braun Aesculap, Tuttlingen, Germany). Furthermore, all operations were performed with the patient in supine position using a minimally invasive anterolateral approach. The operative target of the cup anteversion was 15°. In no case was the cup fixed using an additional screw.

The imageless navigation of the cup was carried out using the OrthoPilot THAplus 3.0 software (B. Braun Aesculap). An infrared reference tracker was attached over a 0.5-cm long skin incision at the ipsilateral iliac spine. Thereafter, infrared recording of the 3 osseal landmarks was carried out: the 2 anterosuperior iliac spines and the pubic symphysis. These osseous landmarks define the anterior pelvic plane (APP) and form the reference for cup positioning throughout the operation.

The cup position was determined intraoperatively by the surgeon, with the help of the navigation system, and recorded. After

the cup was implanted, the stem preparation was performed without navigation. An anteversion of approximately 15° for the rotation of the stem was desired.

Computed tomography of the pelvis and of the femur (Somatom Sensation 64, Siemens Healthcare Sector, Forchheim, Germany), from the anterosuperior iliac spine to the femoral condyles, was performed postoperatively on all patients according to a standardized procedure (120 kV, 50 mA, collimation 64 × 0.6 mm, reconstructed layer thickness 1 mm).

We used a 3D reconstruction of the femur and of the pelvis using specialized software (AMIRA software; Mercury Computer Systems, Chelmsford, Massachusetts) was performed.¹⁷

In order to calculate the femoral anteversion, a condylar plane was defined from the most dorsal point of the two dorsal femoral condyles to the cranial point of the greater trochanter (Figure 1). A second plane (anteversion plane) was defined from the midpoint of the conus, the midpoint of the prosthesis stem and the stem tip. The angle between these two planes defined the anteversion of the prosthesis stem (Figure 1).

To form an osseous reference system for the postoperative cup evaluation, the left and right anterosuperior iliac spines (LASIS and RASIS) and the pubic symphysis were identified to calculate the APP (Figure 2).

The normal vector of the APP plane is the cross-product of the vectors, between the previously described osseous landmarks.

The acetabular cup orientation was determined by acquiring a sufficient number of points (30-40) on the acetabular cup rim. A least-square-approximated plane was created through these points to define the acetabular cup plane. A normal cup vector was created from the deepest point of the acetabular cup and projected orthogonally to the acetabular cup plane. The APP was projected in parallel through the origin of the normal cup vector to define the projected APP. The angle between the normal cup vector and its projection onto the projected APP defines the cup anteversion (Figure 2).

From the projected APP, a sagittal plane through the origin of the normal cup vector was defined. The angle between the projection of the normal cup vector onto the projected APP and the border of the

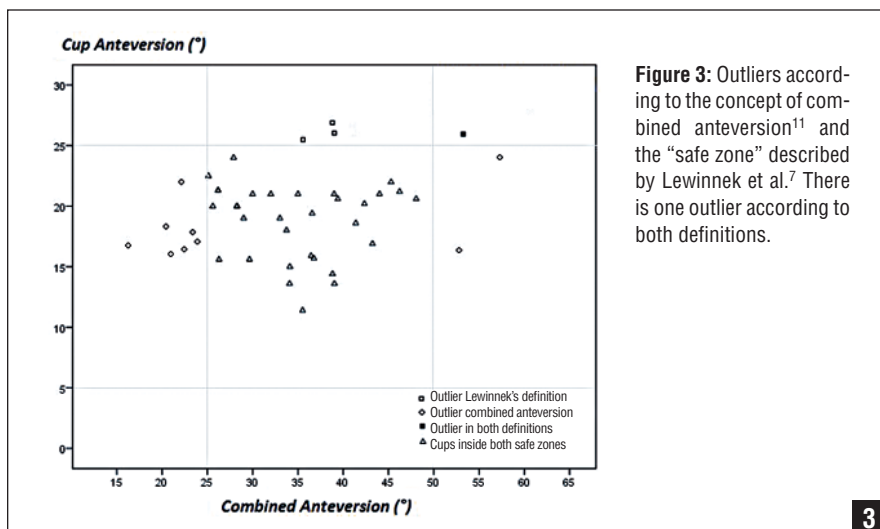


Figure 3: Outliers according to the concept of combined anteversion¹¹ and the “safe zone” described by Lewinnek et al.⁷ There is one outlier according to both definitions.

sagittal plane and the projected APP define the cup abduction (Figure 2).

These calculations are based on Murray’s radiologic definitions.¹⁸ The APP rather than the coronal plane was used as a reference. All results in this study are represented according to the radiologic definition proposed by Murray to compare them with the “safe zone” proposed by Lewinnek.^{7,18}

Means, standard deviations, and ranges were determined for the measurements. When comparing outliers, the Fisher exact test was used.

RESULTS

Data from 46 patients were collected and evaluated. All patients were included in the study. No patient suffered from early complications. There were no dislocations or periprosthetic fractures. The 46 patients were comprised of 21 women and 25 men. Average patient age was 68.7 years (range, 58-82). In the 3D CT analyses, we found a combined anteversion of 34.4° (range, 16.3°-57.3°; SD±9.3°). Taking into consideration the combined anteversion zone (25°-50°) according to Dorr,¹⁴ we found 10 outliers (22%). The mean stem anteversion was 14.9° (range, -5° to 39°; SD±9.1°).

The mean cup anteversion alone was 19.5° (range, 11°-27°; SD±3.7°). Taking

into account the anteversion of Lewinnek’s “safe zone,” 5 of 46 cups were outliers (11%), and according to the concept of combined anteversion, 10 of 46 implants were outliers (22%) (Figure 3). This difference was not statistically significant ($P=.26$). One endoprosthesis in 46 (2%) was an outlier according to both definitions (Figure 3). This was a statistically significant finding when using the concept of combined anteversion ($P=.007$), but it was not statistically significant when using Lewinnek’s “safe zone” ($P=.2$) (Figure 3).

DISCUSSION

Recently, the range of motion of an endoprosthesis without impingement has become increasingly important. Over the past few years, however, for reasons of improved patient function, the head size of the endoprosthesis has been increased and the conus thickness reduced.⁸ However, these implant improvements and the resulting hip joint function are dependent on accurate cup and stem position after THA.^{1,4,7,10,12,14}

The isolated intraoperative attention on either the stem or cup position during THA can result in errors. For example, an anterior impingement during flexion of the hip may result when the cup and the stem are implanted with a slight anteversion, even when one component is

positioned within the permitted range of implant position.^{7,12}

In this study, we compared the outliers between the concept of combined anteversion and the anteversion values of Lewinnek’s “safe zone.”^{7,14}

The use of a navigation system ensured a greater accuracy during positioning of the acetabular components.^{5,6,15,16} When using a pointer-based navigation system, previous studies showed cup outliers of 7% to 20%.^{6,19} Using an ultrasound-based navigation system, this accuracy could be improved further.¹⁷ The observations made in our study, that is, 11% cup outliers, is comparable with previously reported data.^{5,6,15,16,19} In those studies and in our study, the “safe zone” according to Lewinnek et al⁷ was used as a reference. However, in none of those studies was the resulting combined (ie, femoral and acetabular) anteversion analyzed.¹⁴

In our retrospective study, we found a combined anteversion of 34.4° (SD±9.3°). Dorr et al,¹⁴ using stem and cup navigation, showed comparable values with a mean combined anteversion of 37.6° (SD±7°). However, Dorr et al¹⁴ observed a lower range (19°-50°) than was seen in our study (16.3°-57.3°).

Despite this low number of outliers regarding the anteversion values for acetabular cup positioning (11%) according to Lewinnek’s “safe zone,” we found 22% outliers when considering combined anteversion (recommended range, 25°-50°). Only 1 endoprosthesis (2%) lay outside both concepts. This indicates a poor correlation between the 2 concepts. The cause lies in the broader range of the stem anteversion.

Thus, in our study in which cementless femur stems were used, a broad range of femoral anteversion was found, although an anteversion of 15° was desired. This finding is in agreement with Dorr et al’s¹⁴ previously reported findings of a broad range of retroversion (8.6°) to anteversion (27.1°) using cementless stems. Other studies that used both cementless and cemented

stems showed a range between 30° retroversion and 45° anteversion.^{20,21}

This allows the conclusion to be drawn that error is more likely than was previously believed when freehand implantation is done. Even when cup navigation is used, unless the resulting combined anteversion is respected, there could be an associated increased risk of impingement and subsequent dislocation of hip endoprosthesis.

The femoral plane, which is defined by the most cranial point of the major trochanter and the dorsal condyles, serves as a reference for the intraoperative determination of femoral anteversion. A source of error during positioning of the femoral components is poor intraoperative determination of the dorsal femoral condyles. Commonly these condyles are determined indirectly, with the knee joint in 90° flexion. A possible source of error with this indirect method is deviation of the flexion axis of the knee joint. Condylar hypoplasia, osteoarthritis degeneration, or ligamentous instability of the knee joint could influence this flexion axis.


These influences could cause substantial rotational errors in stem position. Therefore, with the leg extended rather than in 90° knee flexion, rotational differences in the prosthetic stem are expected. Direct visualization of the dorsal femoral condyles is desirable.

Another potential source of error is the uncertain influence of the anteroposterior isthmus and the antecurvature of the femur. However, this geometry of the proximal femur appears to have a greater effect in the case of thicker cortices of type A than in type C shapes, in which retroversion of the femoral components could result.¹¹

CONCLUSION

For reasons of functionality, as well as for long-term implant survival, the stem position, in conjunction with the cup, is of paramount significance. Imageless navigation is a method for positioning the acetabular component of the THA more precisely regarding Lewinnek's

“safe zone” than during freehand THA implantation. However, because of the broad range of possible cementless stem positions, there is a statistically significant difference between the concept of the combined anteversion and Lewinnek's “safe zone.”

Thus, it is necessary to respect the positioning of the femoral stem. If the concept of combined anteversion is regarded, then the surgeon should match the cup anteversion to the resulting stem anteversion. Whether the navigation of the stem implantation or the femur-first technique can bring about this improvement needs to be determined in future studies. 

REFERENCES

- Biedermann R, Tonin A, Krismer M, Rachbauer F, Eibl G, Stockl B. Reducing the risk of dislocation after total hip arthroplasty: the effect of orientation of the acetabular component. *J Bone Joint Surg Br.* 2005; 87(6):762-769.
- Jolles BM, Zangger P, Leyvraz PF. Factors predisposing to dislocation after primary total hip arthroplasty: a multivariate analysis. *J Arthroplasty.* 2002; 17(3):282-288.
- Kennedy JG, Rogers WB, Soffe KE, Sullivan RJ, Griffen DG, Sheehan LJ. Effect of acetabular component orientation on recurrent dislocation, pelvic osteolysis, polyethylene wear, and component migration. *J Arthroplasty.* 1998; 13(5):530-534.
- Del Schutte H Jr, Lipman AJ, Bannar SM, Livermore JT, Ilstrup D, Morrey BF. Effects of acetabular abduction on cup wear rates in total hip arthroplasty. *J Arthroplasty.* 1998; 13(6):621-626.
- Ybinger T, Kumpan W, Hoffart HE, Muschalik B, Bullmann W, Zweymuller K. Accuracy of navigation-assisted acetabular component positioning studied by computed tomography measurements: methods and results. *J Arthroplasty.* 2007; 22(6):812-817.
- Parratte S, Argenson JN. Validation and usefulness of a computer-assisted cup-positioning system in total hip arthroplasty. A prospective, randomized, controlled study. *J Bone Joint Surg Am.* 2007; 89(3):494-499.
- Lewinnek GE, Lewis JL, Tarr R, Compere CL, Zimmerman JR. Dislocations after total hip-replacement arthroplasties. *J Bone Joint Surg Am.* 1978; 60(2):217-220.
- D'Lima DD, Urquhart AG, Buehler KO, Walker RH, Colwell CW Jr. The effect of the orientation of the acetabular and femoral components on the range of motion of the hip at different head-neck ratios. *J Bone Joint Surg Am.* 2000; 82(3):315-321.
- McKibbin B. Anatomic factors in the stability of the hip joint in the newborn. *J Bone Joint Surg Br.* 1970; 52(1):148-159.
- Dorr LD, Wan Z, Malik A, Zhu J, Dastane M, Deshmene P. A comparison of surgeon estimation and computed tomographic measurement of femoral component anteversion in cementless total hip arthroplasty. *J Bone Joint Surg Am.* 2009; 91(11):2598-2604.
- Dorr LD, Faugere MC, Mackel AM, Gruen TA, Bognar B, Malluche HH. Structural and cellular assessment of bone quality of proximal femur. *Bone.* 1993; 14(3):231-242.
- Widmer KH, Zurfluh B. Compliant positioning of total hip components for optimal range of motion. *J Orthop Res.* 2004; 22(4):815-821.
- Maruyama M, Feinberg JR, Capello WN, D'Antonio JA. The Frank Stinchfield Award: morphologic features of the acetabulum and femur: anteversion angle and implant positioning. *Clin Orthop Relat Res.* 2001; (393):52-65.
- Dorr LD, Malik A, Dastane M, Wan Z. Combined anteversion technique for total hip arthroplasty. *Clin Orthop Relat Res.* 2009; (467):119-127.
- Dorr LD, Malik A, Wan Z, Long WT, Harris M. Precision and bias of imageless computer navigation and surgeon estimates for acetabular component position. *Clin Orthop Relat Res.* 2007; (465):92-99.
- DiGioia AM III, Jaramaz B, Plakseychuk AY, et al. Comparison of a mechanical acetabular alignment guide with computer placement of the socket. *J Arthroplasty.* 2002; 17(3):359-364.
- Hasart O, Poeplau BM, Asbach P, Perka C, Wassilew GI. Ultrasound-based navigation and 3D CT compared in acetabular cup position. *Orthopedics.* 2009; 32(10 Suppl):6-10.
- Murray DW. The definition and measurement of acetabular orientation. *J Bone Joint Surg Br.* 1993; 75(2):228-232.
- Kalteis T, Handel M, Bathis H, Perlick L, Tingart M, Grifka J. Imageless navigation for insertion of the acetabular component in total hip arthroplasty: is it as accurate as CT-based navigation? *J Bone Joint Surg Br.* 2006; 88(2):163-167.
- Pierchon F, Pasquier G, Cotten A, Fontaine C, Clarisse J, Duquenooy A. Causes of dislocation of total hip arthroplasty. CT study of component alignment. *J Bone Joint Surg Br.* 1994; 76(1):45-48.
- Wines AP, McNicol D. Computed tomography measurement of the accuracy of component version in total hip arthroplasty. *J Arthroplasty.* 2006; 21(5):696-701.