

A New Tool for Measuring Cup Orientation in Total Hip Arthroplasties from Plain Radiographs

Chen-Kun Liaw, MD; Sheng-Mou Hou, MD, PhD, MPH; Rong-Sen Yang, MD, PhD; Tai-Yin Wu, MD; and Chiou-Shann Fuh, PhD

Orientation of the hip cup is important in total hip arthroplasties. Orientation includes abduction (inclination) and anteversion. Anteversion can be considered as true (anatomic) and planar (radiographic) anteversion. Some measurement methods either are too complicated or are less precise. We developed a new protractor to measure cup orientation using postoperative anteroposterior radiographs centered at the hip. The new protractor measures true and planar anteversion and abduction easily and precisely. We verified its accuracy using a software simulator and simulated 45 radiographs of total hip arthroplasties with 15 different anteversions ranging from 15°–29° and 45 actual radiographs of total hip arthroplasties. We then measured the planar anteversion with our method and the method of Lewinnek et al. Maximal errors were 3° and 2.61°, respectively, and mean errors were 0.96° and 1.2°, respectively. The standard deviations were 0.74° with our method and 0.57° with the method of Lewinnek et al. For the real radiographs, the mean of absolute difference between the two methods was 1.34°, and the standard deviation was 1.13°. We found no difference between the two methods and no difference in our findings compared with those of Pradhan.

Level of Evidence: Diagnostic study, level II.

According to the American Academy of Orthopaedic Surgeons (AAOS), more than 172,221 total hip arthroplasties (THAs) are performed annually in the United States.¹ Excellent outcomes require technically accurate surgery including proper prosthesis positioning and soft tissue man-

agement. The term positioning includes location and orientation. Orientation implies two parameters: abduction and anteversion.

Abduction can be measured easily using an ordinary protractor on an anteroposterior (AP) radiograph. Abduction is the angle between the long axis of the ellipse formed by the cup and the horizontal line of the pelvis. However, true (anatomic) and planar (radiographic) anteversion are more difficult to measure. Numerous methods for measurement have been reported.^{2–6,8–12} The method of Olivecrona et al requires a computed tomography (CT) scan and special software.⁹ The other methods require high-quality AP radiographs with good patient positioning and radiographic conditioning. The methods of Lewinnek et al⁵ and Pradhan¹⁰ are trigonometric methods, which require a numerical table or a calculator. Long and short axes of the ellipse need to be drawn in the method of Lewinnek et al⁵ and another perpendicular axis located 1/5 of the distance along the long axis needs to be drawn in the method of Pradhan.¹⁰ The methods of Fabeck et al⁴ and that of Widmer¹² do not require a calculator. The method of Fabeck et al⁴ takes a longer time to determine the center of the circle. Widmer's¹² method is better, but it is not very precise in determining abduction.

We introduce a simple new protractor used to measure anteversion and abduction using an AP radiograph of the pelvis.

MATERIALS AND METHODS

According to Murray's definition,⁸ if the acetabulum axis (or normal vector of the acetabulum plane) (Fig 1A) is defined, then the true (anatomic) anteversion can be measured by projecting the acetabulum axis onto the transverse plane (Fig 1B). Planar (radiographic) anteversion is measured by projecting the acetabulum axis to the plane perpendicular to the coronal plane and the acetabulum plane (Fig 1C). Flexion (operative anteversion) is measured by projecting the same vector onto the sagittal plane (Fig 1D). Abduction (inclination) is measured by projecting that

Received: April 22, 2005

Revised: November 1, 2005; March 18, 2006

Accepted: April 10, 2006

From the En Chu Kong Hospital, Taipei Hsien, Republic of China.

Each author certifies that he or she has no commercial associations (eg, consultancies, stock ownership, equity interest, patent/licensing arrangements, etc) that might pose a conflict of interest in connection with the submitted article.

Correspondence to: Chiou-Shann Fuh, PhD, 4F, No. 26, Alley 2, Lane 19, Shin-Shing Street, Shan-Jia, Shu-Lin City, Taipei County, Taiwan. Phone: 886-2-23936577; Fax: 886-2-23936577; E-mail: 00901@km.eck.org.tw.

DOI: 10.1097/01.blo.0000223988.41776.fa

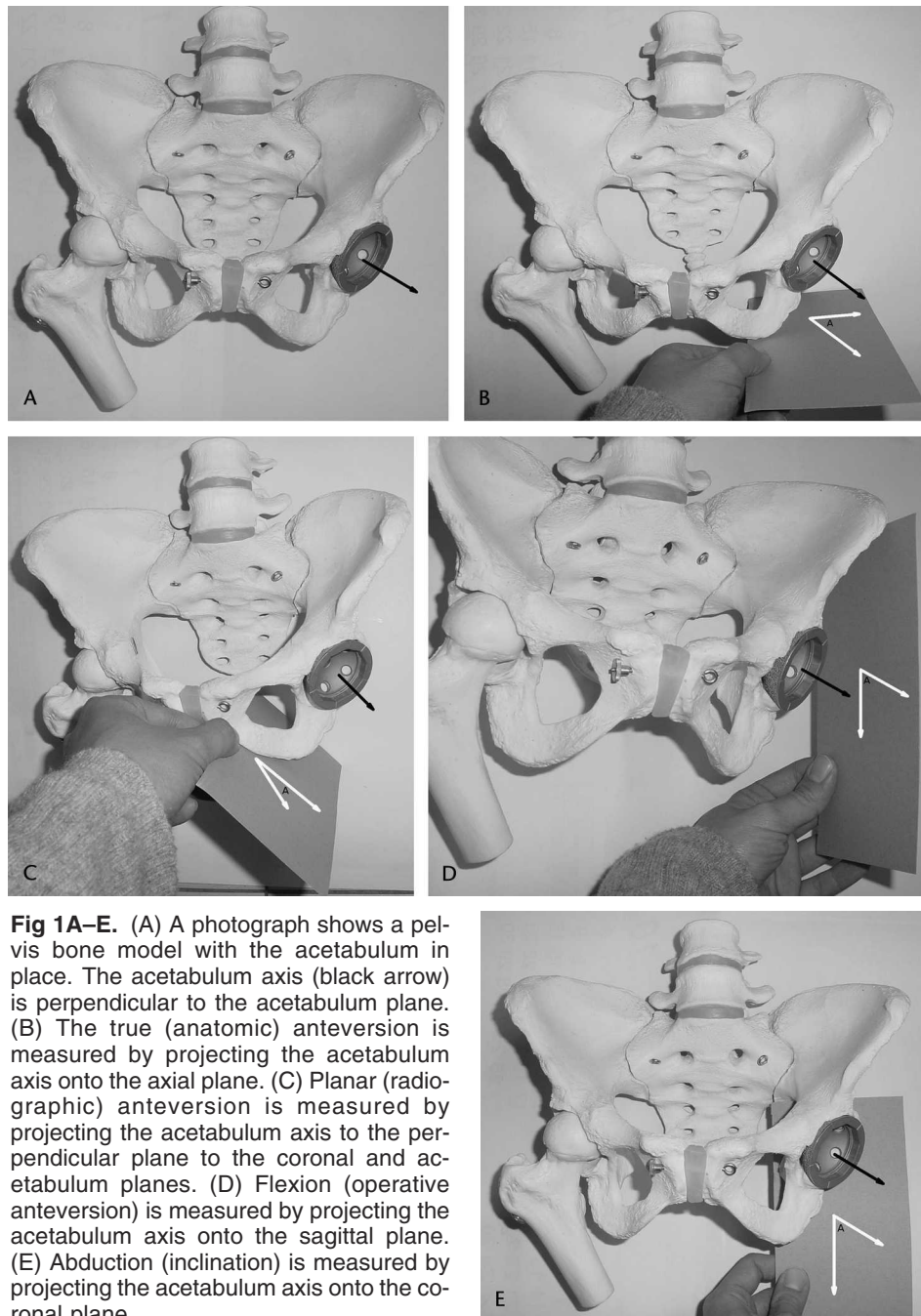


Fig 1A–E. (A) A photograph shows a pelvis bone model with the acetabulum in place. The acetabulum axis (black arrow) is perpendicular to the acetabulum plane. (B) The true (anatomic) anteversion is measured by projecting the acetabulum axis onto the axial plane. (C) Planar (radiographic) anteversion is measured by projecting the acetabulum axis to the perpendicular plane to the coronal and acetabulum planes. (D) Flexion (operative anteversion) is measured by projecting the acetabulum axis onto the sagittal plane. (E) Abduction (inclination) is measured by projecting the acetabulum axis onto the coronal plane.

vector onto the coronal plane (Fig 1E).⁸ These angles are not independent, because when one angle is changed, so are the others, unless the vector lies in one of the four planes.

An accepted method of measuring the opening angle α_p (planar version) is based on the respective lengths of the short (s_p) and long (l_p) axes of the elliptical outline of the shell in the AP radiograph (Fig 2A).⁵ Using these quantities, the planar version α_p may be calculated using the formula:

$$\alpha_p = \sin^{-1}(s_p/l_p) \quad (1)$$

The l is Line AB where the s is Line CD (Fig 2A). When considering the true version, the principle is the same, but the equation must be modified to Equation 1.1.¹¹ The s , becomes the distance between the center of the ellipse and the intersection of the horizontal line passing through the center of the ellipse, as shown by Line EF (Fig 2B). The l , becomes $1/2$ the length of the long axis, as shown by Line DE (Fig 2B).¹¹

$$\alpha_t = \sin^{-1}(s_t/l_t) \quad (1.1)$$

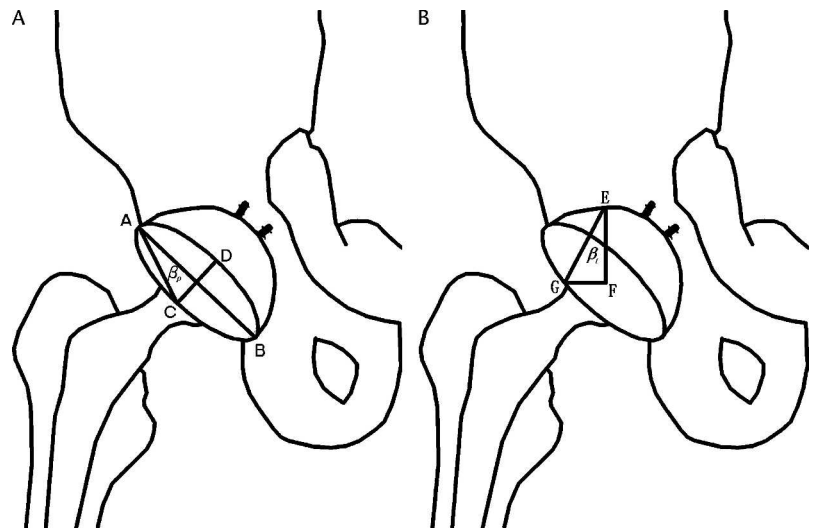


Fig 2A–B. (A) A diagram shows the measurements we used on the AP radiograph. We drew a line from A to B, with point C as the midpoint of the inferior curve of the ellipse. We then drew a line from A to C. β_p is the angle formed by Line AB and Line AC. (B) When measuring true anteversion of the AP radiograph, we drew a line from point E (the top-most point of the semicircle) to point F (the center of the ellipse). We then selected point G by the intersection of the horizontal line passing through point F, and drew a line from E to G. The angle β_t is formed by Lines EF and EG.

This method requires a table or calculator with an inverse sine (\sin^{-1}) function and is not convenient. We designed a new protractor to replace the cumbersome calculations.

The method for measuring planar version is as follows: (1) Draw a line across the maximal diameter of the ellipse in the AP radiograph, such as Line AB (Fig 2A);

(2) Determine point C midway on the ellipse (Fig 2A), which is the intersection of ellipse and the line perpendicular and going through the midpoint of AB. (3) Draw another line from the apex A to point C (Fig 2A); and (4) Use an ordinary protractor to measure the angle β_p (Fig 2A), which is formed by Lines AC and AB.

To measure true version: (1) Draw a line from point E (the top-most point of the semicircle) to point F (the center of the ellipse) (Fig 2B); (2) Determine point G (Fig 2B) by the intersection of the horizontal line passing through point F; (3) Draw a line from point E to point G (Fig 2B); and (4) Use an ordinary protractor to measure the angle β_t (Fig 2A), which is formed by lines EG and EF.

$$\beta_p = \tan^{-1}(s_p/l_p) \tag{2}$$

$$\beta_t = \tan^{-1}(s_t/l_t) \tag{2.1}$$

This is deduced from simple trigonometry. In Situation 1, we measured planar version; s_p was the length of short axis and l_p was the length of long axis (Fig 2A). In Situation 2, we measured true version; s_t was the length of line FG and l_t was the length of Line EF (Fig 2B).

$$\alpha_p = \sin^{-1} \tan \beta_p \text{ from Equation 1 and Equation 2} \tag{3}$$

$$\alpha_t = \sin^{-1} \tan \beta_t \text{ from Equation 1.1 and Equation 1} \tag{3.1}$$

$$\beta_p = \tan^{-1} \sin \alpha_p \text{ from Equation 3} \tag{4}$$

$$\beta_t = \tan^{-1} \sin \alpha_t \text{ from Equation 3.1} \tag{4.1}$$

Using traditional procedures, one would measure angles β_p and β_t with an ordinary protractor, then use equations 3 and 3.1 to

calculate the true and planar versions. By equation 4, we make the first part of our protractor by marking α_p (the version) with β_p (the real angle). This special protractor can be used to measure α_p directly, with no need for calculations (Fig 3). For the second part, we used an ordinary protractor to measure abduction. We explained how to measure α_p directly, and a similar way to measure α_t .

To use the protractor, we aligned the base line of the protractor with the long axis of the ellipse to read the planar version angle defined by point C (Fig 4A–B). To measure the true version angle, we aligned the base line of the protractor with Line EF, and then read the true version angle defined by point G (Fig 4C–D).

When measuring the planar version, part 2 of our protractor (an ordinary protractor) can be used simultaneously to measure

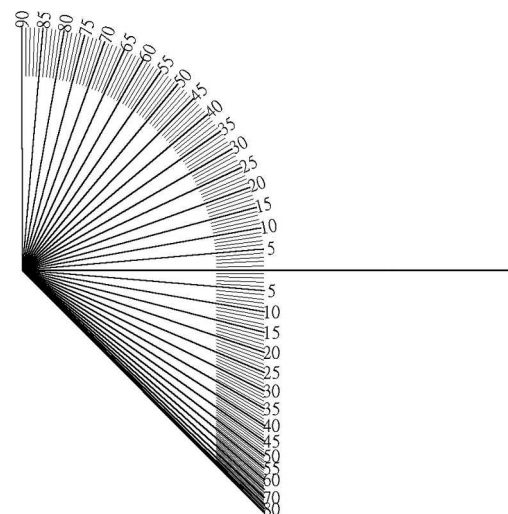


Fig 3. The upper part of our protractor is the same as an ordinary protractor used to measure the abduction angle. The lower part is used to measure the anteversion angle.

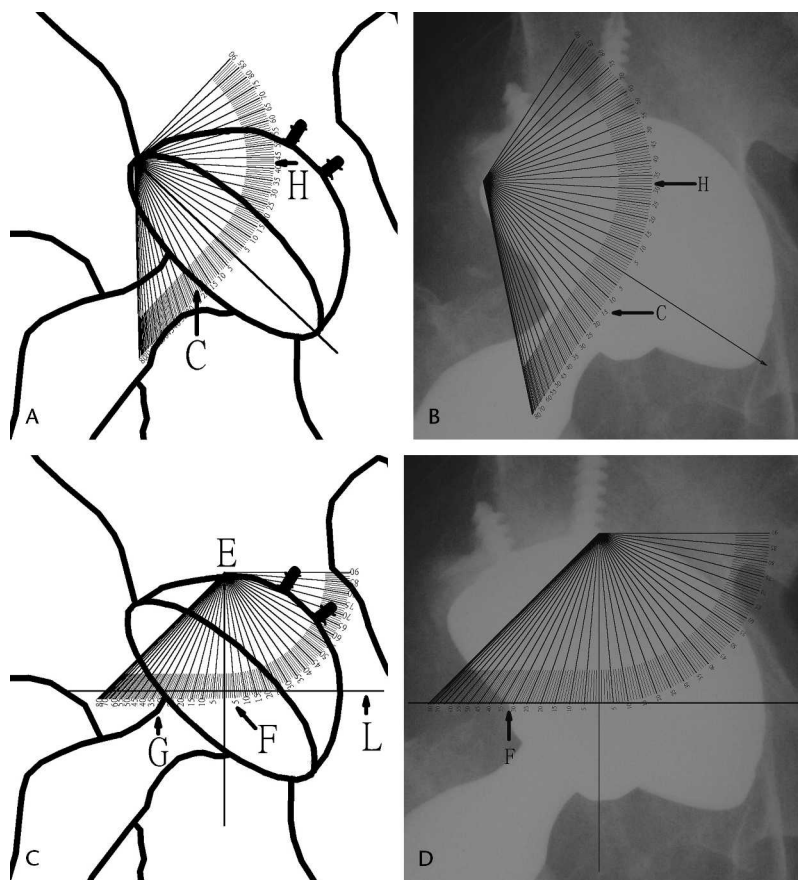


Fig 4A–D. (A) We estimated Point C (arrow) to determine a 20° planar anteversion angle. The horizontal line of the pelvis (parallel to the line passing through both teardrop landmarks) (arrow H) was 41°, which determined the abduction angle. (B) The protractor was used with a real radiograph. It shows a planar anteversion angle of 16° and an abduction angle of 32°. (C) The base-line of the protractor was aligned with point E (the top-most point of the semicircle) and point F (the center of the ellipse). We determined point G by the intersection of the horizontal line L passing through point F. The true version angle was 34° as measured by point G. (D) The anteversion angle was 32° when using the protractor with a real radiograph.

the abduction angle. We can read this angle by the protractor of a horizontal line, which is parallel to the line passing through both teardrop landmarks, as indicated by the arrow labeled H (Fig 4A–4B).

We determined the accuracy of our method by comparing it with the trigonometric method.^{5,6} We used software simulating 45 radiographs of THAs with 15 different anteversions ranging from 15°–29° (Fig 5A). We also collected 45 actual radiographs of THAs. These simulated and real radiographs were printed on paper. One of the authors (C.K.L.) measured the planar version of the 45 simulated and 45 real radiographs using the method described by Lewinnek et al⁵ (Fig 5B) and 1 week later with our method (Fig 5C). We randomly ordered the simulated radiographs on each measurement.

The two errors were compared with a two-sample Student’s t test. Significance was set at the $p < 0.05$ level.

RESULTS

The median errors were within 1° with our method and 1.23° with the method of Lewinnek et al. Maximal errors were 3° with our method and 2.61° with the method of Lewinnek et al, and the mean errors were 0.96° and 1.2°, respectively. The standard deviation was 0.74° with our

method and 0.57° with the method of Lewinnek et al. (Fig 6) There was no statistical difference between the two methods. For the real radiographs, the mean of absolute difference between the two methods was 1.34°, and the standard deviation was 1.13°.

DISCUSSION

Current methods of measuring the version angle require good quality radiographs, which means a nearly perfect AP projection without rotation on the transverse and longitudinal axes, and centered at the hip. If the projection is not perfect, there will be measurement errors. If there is a 5° rotation on the transverse axis, then it will cause a 5° error in the flexion angle. A change in one angle causes the other three angles to change. The changes in the other three angles (true version, planar version, and abduction) will be smaller than the flexion angle. Similarly, for the longitudinal axis, a 5° rotation will cause a 5° error in the true version. The error of the other three angles will be smaller. The detailed mathematical formulas were described by Murray.⁸






Fig 5A–C. (A) The software simulator is shown. The user can adjust anteversion and wear. (B) The simulated radiographs were printed on paper to measure the long axis of the ellipse to determine planar anteversion (the method of Lewinnek et al⁵). (C) A photograph shows our protractor used for measuring planar anteversion.

No solution exists for perfect patient positioning using the plain radiograph method. However, CT can solve this problem. With a virtual plane as described by McKibben (including the anterior superior iliac spines and the pubic tubercles), the software can measure the angle between the

Errors of Measurements

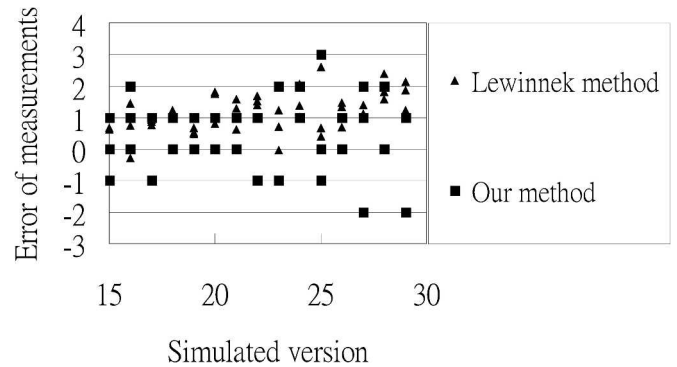


Fig 6. This graph shows the errors of measuring the simulated version. The method of Lewinnek et al⁵ and our method showed good correlation to the real version. There is no systematic variation between the two methods.

cup and plane.⁹ The method described by Olivecrona et al⁹ is excellent but unpractical because of the high cost of CT and the risk of radiation exposure. The relationship between position and version were discussed by Moritz et al.⁷

The greatest error in our method was finding point C (for planar version) and point F (for true version). In most patients, the femoral head obscured these points. Pradhan’s solution was to measure the ellipse by the length of the perpendicular axis located 1/5 of the distance along the long axis from the apex to avoid the obscured region.¹⁰ The point is on middle part of the ellipse. It follows the rules of an ellipse which makes it easier to estimate. The mean error and standard deviation of error from Pradhan’s data were 0.88 and 0.65, respectively.¹⁰

Bias in anteversion measurements using radiographs is inevitable because of measuring a three-dimensional object using a two-dimensional image projection. Some methods require using a ruler to measure two or more distances which then are used to make various calculations.^{5,10} For example, The method of Lewinnek et al needs measurement of the long and short axes of the ellipse.⁵ However, with every measurement, operational errors are inevitable. Therefore, we think our method is superior to that of Lewinnek et al. However, this could be the effect of operational error. Both methods have similar errors; possibly because the femoral head obscured measurement points in our method caused a similar error to the operational error in the method by Lewinnek et al. The method of Fabeck et al does not require ruler measurements, as it is determined by lines drawn on a radiograph.⁴ Our method requires only one measurement, which re-

duces the operational error. Widmer's method calculates the measurement using only one step, but there are errors with different abduction angles.¹² Our method can measure without influencing abduction.

Our method is a simplified version of the method of Lewinnek et al.⁵ However, we only compared its ability to measure planar version. Measuring simulated and real radiographs shows little difference between the two methods. We can extend the result to the true version. When measuring a true version, we need to draw a horizontal line on the radiograph. However, it is still convenient when compared with other measurement methods. Our new protractor allows measurement of true version, planar version, and abduction. Additional studies are needed to provide a gold standard for measurement.

References

1. AAOS. Total Hip Replacement. Available at: <http://orthoinfo.aaos.org>. Accessed October 23, 2005.
2. Ackland MK, Bourne WB, Uhthoff HK. Anteversion of the acetabular cup: measurement of angle after total hip replacement. *J Bone Joint Surg Br.* 1986;68:409-413.
3. Coventry MB, Beckenbaugh RD, Nolan DR, Ilstrup DM. 2,012 total hip arthroplasties: a study of postoperative course and early complications. *J Bone Joint Surg Am.* 1974;56:273-284.
4. Fabeck L, Farrokh D, Tolley M, Descamps PY, Gebhart M, Delince P. A method to measure acetabulum cup anteversion after total hip replacement. *Acta Orthop Belg.* 1999;65:485-491.
5. Lewinnek GE, Lewis JL, Tarr R, Compere CL, Zimmerman JR. Dislocations after total hip-replacement arthroplasties. *J Bone Joint Surg Am.* 1978;60:217-220.
6. McLaren RH. Prosthetic hip angulations. *Radiology.* 1973;107:705-706.
7. Moritz T, Ulrich L, Klaus-Arno S, Matthias W, Kai B, Frank L. Anatomic referencing of cup orientation in total hip arthroplasty. *Clin Orthop Relat Res.* 2005;436:144-150.
8. Murray DW. The definition and measurement of acetabular orientation. *J Bone Joint Surg Br.* 1993;75:228-232.
9. Olivecrona H, Weidenhielm L, Olivecrona L, Beckman MO, Stark A, Noz ME, Maguire GQ, Zeleznik MP, Svensson L, Jonson T. A new CT method for measuring cup orientation after total hip arthroplasty: a study of 10 patients. *Acta Orthop Scand.* 2004;75:252-260.
10. Pradhan R. Planar anteversion of the acetabular cup as determined from plain anteroposterior radiographs. *J Bone Joint Surg Br.* 1999;81:431-435.
11. Visser JD, Konings JG. A new method for measuring angles after total hip arthroplasty: a study of the acetabular cup and femoral component. *J Bone Joint Surg Br.* 1981;63B:556-559.
12. Widmer KH. A simplified method to determine acetabular cup anteversion from plain radiographs. *J Arthroplasty.* 2004;19:387-390.